

## Case Report

# Acute Traumatic Rupture of the Thoracic Aorta: An Endovascular Approach

**Christos Bekos, MBBS, MSc, PhD**

Consultant Vascular Surgeon, Head of the Unit of Vascular Surgery, Nicosia General Hospital, Cyprus

**Ilianna Armata, BSc**

Medical Student at St George's, University of London medical programme, Delivered in Cyprus by the University of Nicosia Medical School, Nicosia, Cyprus

**Aria Antoniadou, BSc, MSc**

Medical Student at St George's, University of London medical programme, Delivered in Cyprus by the University of Nicosia Medical School, Nicosia, Cyprus

**Eleana Ferrari, BSc, MSc**

Medical Student at St George's, University of London medical programme, Delivered in Cyprus by the University of Nicosia Medical School, Nicosia General Hospital, Cyprus

**Andreas Hadjipolycarpou, MD**

Unit of Vascular Surgery, Nicosia General Hospital, Nicosia, Cyprus

**Correspondence:** Christos Bekos, Consultant Vascular Surgeon, Head of the Unit of Vascular Surgery, Nicosia General Hospital, Nicosia, Cyprus e-mail: b.chris@cytanet.com.cy

### Abstract

Over three quarters of the patients that suffer an acute traumatic aortic rupture die at the scene of the accident. Traditional open surgery repair of aortic transection is associated with significant morbidity and a perioperative mortality rate as high as 50%. The high morbidity and mortality rate combined with the evolution of endovascular techniques and the many practical advantages compared to open surgery, tend to establish the endovascular technique as the favored approach for this injury pattern.

**Key words:** aortic injury, acute traumatic aortic rupture, aortic transection, aortic repair, endovascular repair, endovascular approach

### Introduction

Traumatic injury of the thoracic aorta, usually caused by blunt trauma, is a notorious vascular injury. Road traffic accidents accounted for over 75% of all cases in most series (Fabian et al., 1997, Williams et al., 1994). Almost 75-90% of the patients die at the scene of accident (Rousseau et al., 2005, Williams et al., 1994).

The majority of injuries occur at the aortic isthmus. At this site, the relatively mobile thoracic aorta joins the fixed arch and the insertion of the ligamentum arteriosum (Botallo's ligament). Traditional open repair of aortic transection is associated with significant morbidity and peri-

operative mortality rate as high as 50% (Rousseau et al., 2005).

Treatment of aortic trauma using endovascular techniques has evolved (TEVAR) and offers many practical advantages compared to open surgery (Pauls et al., 2007, Reed et al., 2006).

One of the most important anatomic characteristics of any lesion allowing endovascular treatment is the presence of an adequate proximal landing zone which corresponds to at least 20mm of non-dissected aortic wall from the origin of the left subclavian artery (LSA) [20mm proximal neck length, from the proximal end of primary entry tear

to the LSA /LCCA (left common carotid artery) along outer curve].

In conclusion growing experience with the endovascular techniques has provided an alternative to this type of aortic traumatic injuries. Experience from this report as well as from the literature review indicates that TEVAR is the favored approach for this injury pattern (Walsh et al., 2008).

## Case Report

### Case

A 20-year old male presented to the emergency department after a car accident with multiple contusions of the head and neck, a fracture of the left clavicle and a blunt thoracic trauma. On admission, the patient was hemodynamically stable. Neurological and orthopedic assessments were performed, with no major neurological deficits or bone fractures noted. On immediate exploration with thoracic computed tomography (CTA), a traumatic thoracic aortic rupture was diagnosed at the level of the isthmus. The CT angiogram confirmed an aortic disruption at the level of isthmus with a pseudoaneurysm formation.

### Endovascular Repair

Subsequently, the patient was transferred to the hybrid suite (hybrid catheterization laboratory). The patient's right arm was prepped to facilitate retrograde vascular access to the right (RT) subclavian artery for the possibility of an angiogram. After groin access was achieved through a right transverse inguinal incision, an intraoperative angiography was performed. Under general anaesthesia, with an introduction of a 0,035 guidewire (Amplatz, superstiff 3m) through puncture of the right common femoral artery was performed. The guidewire was fed through to the root of the aortic arch with a JR4 guiding catheter advanced with a normal 0,035 PTFE wire. This was subsequently replaced with the stiff wire. An angiographic catheter (pigtail) was inserted at the right brachial artery percutaneously, up to the origin of the ipsilateral subclavian artery (Figure 1).

The stent was advanced over the wire through to the aortic arch under fluoroscopy guidance. An angiography was performed via a pigtail catheter

placed in the right subclavian artery that identified the lesion of the proximal and distal landing zone which were marked (Figure 2).

The stent graft (GORE TAG 262610, Thoracic Endoprosthesis, WL Gore Flagstaff, AZ, USA) was deployed with partial coverage of the subclavian ostium. A three-lobular balloon was gently inflated at the proximal landing zone for better wall apposition due to the angulation of the aortic arch in the young male. A post-operative angiography was performed that showed good expansion of the stent-graft without evidence of any type of endoleak or extravasation (Figure 3).

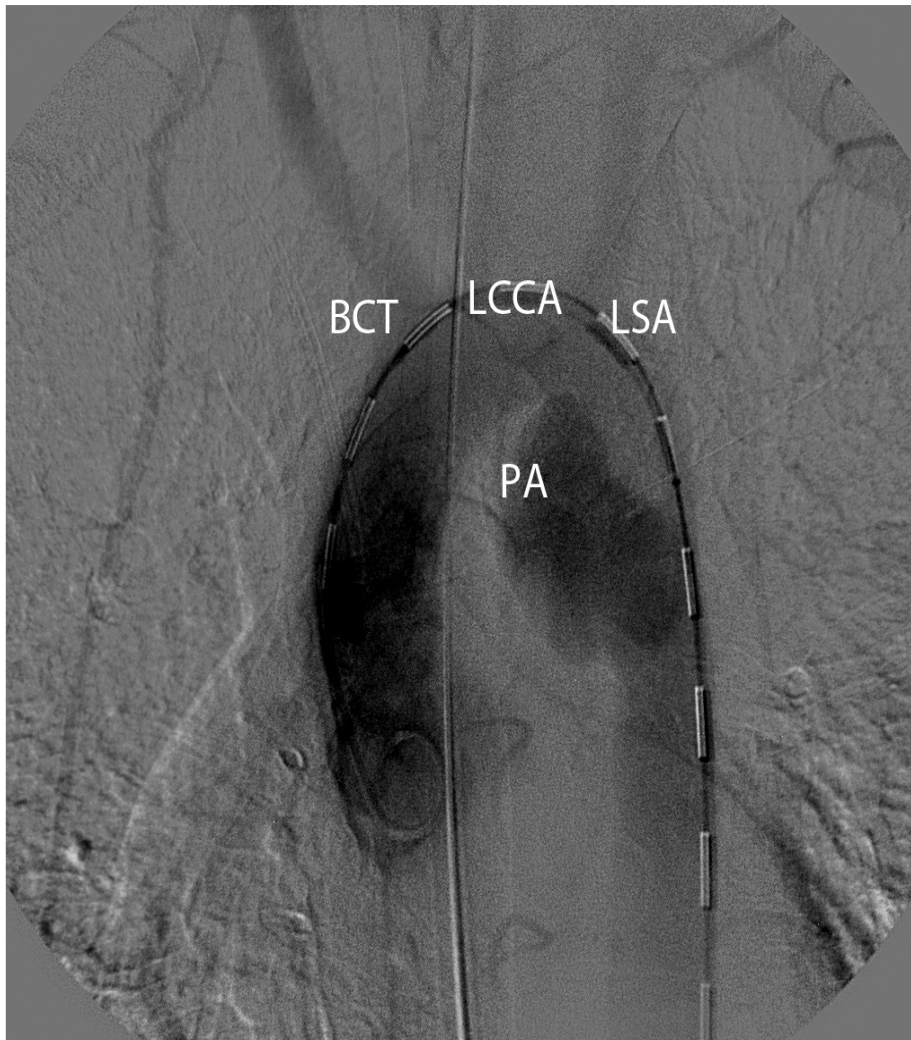
### Postoperative Course

On awakening, the patient had satisfactory perfusion of the right upper limb (difference in blood pressure between the two proximal limbs was 35 mmHg), with no neurological sequelae. On repeated CT scan 3 months postoperatively, the graft remained at its initial position and complete closure of the entry point, with no signs of endoleak or structural stent deformity.

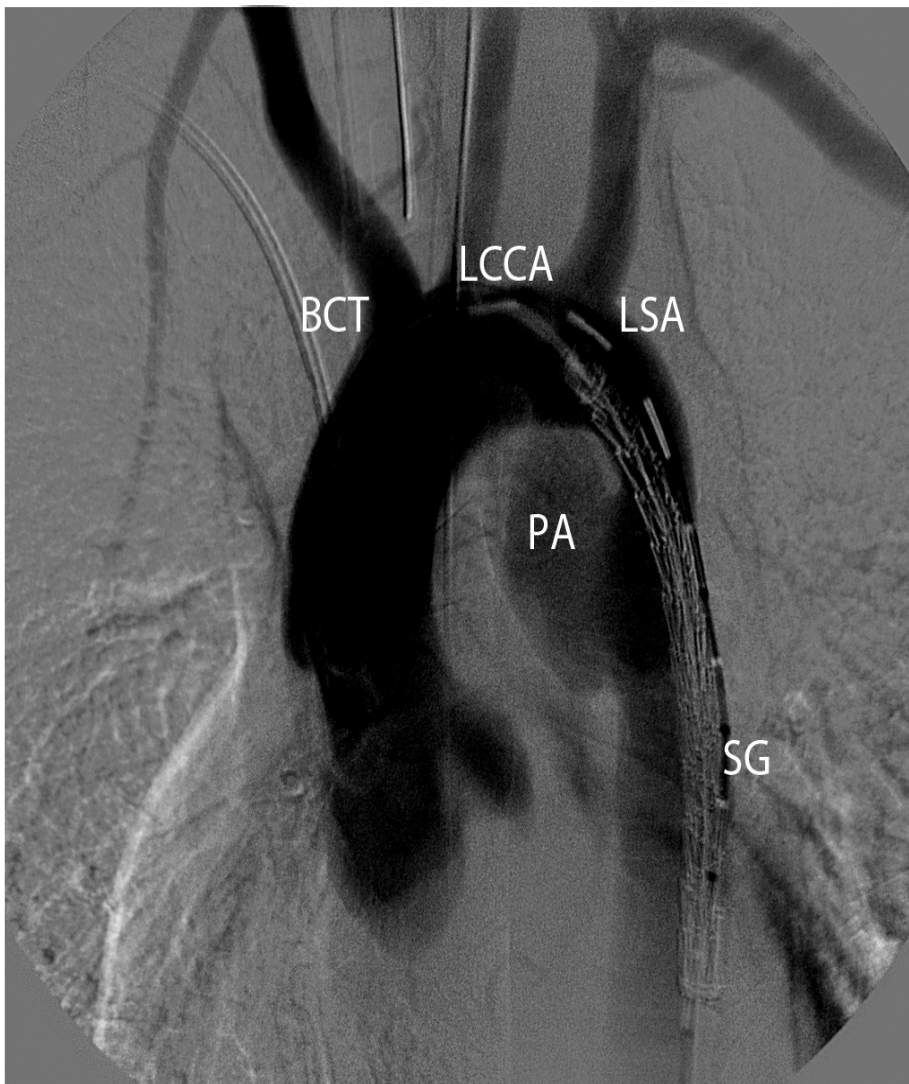
### Discussion

Rupture of the thoracic aorta after a blunt trauma is a life-threatening emergency. Approximately 18-20% of deaths in car accidents are due to acute traumas of the isthmus, becoming the second most common cause of death following brain damage. During a car accident, the abrupt deceleration that occurs on impact during a collision causes more than 80% of thoracic aorta injuries at the level of the aortic isthmus. Only 15-20% of patients with blunt thoracic trauma will make it to the hospital despite immediate assessment, with mortality rates at just over 20%, and 3-14% of patients becoming paraplegic. Collateral injuries are mainly responsible for the high morbidity and mortality rates of these patients (Cullen et al., 2014, Di Marco et al., 2013).

Today the rapid evolution of endovascular surgery and its extensions to thoracic aortic diseases allow the treatment of aortic isthmus rupture via a simple to implement stent-graft placement. This avoids classic surgical repair through an open thoracotomy which liberates the patients from the complications of major surgical trauma and reduces the high rates of perioperative morbidity and mortality.

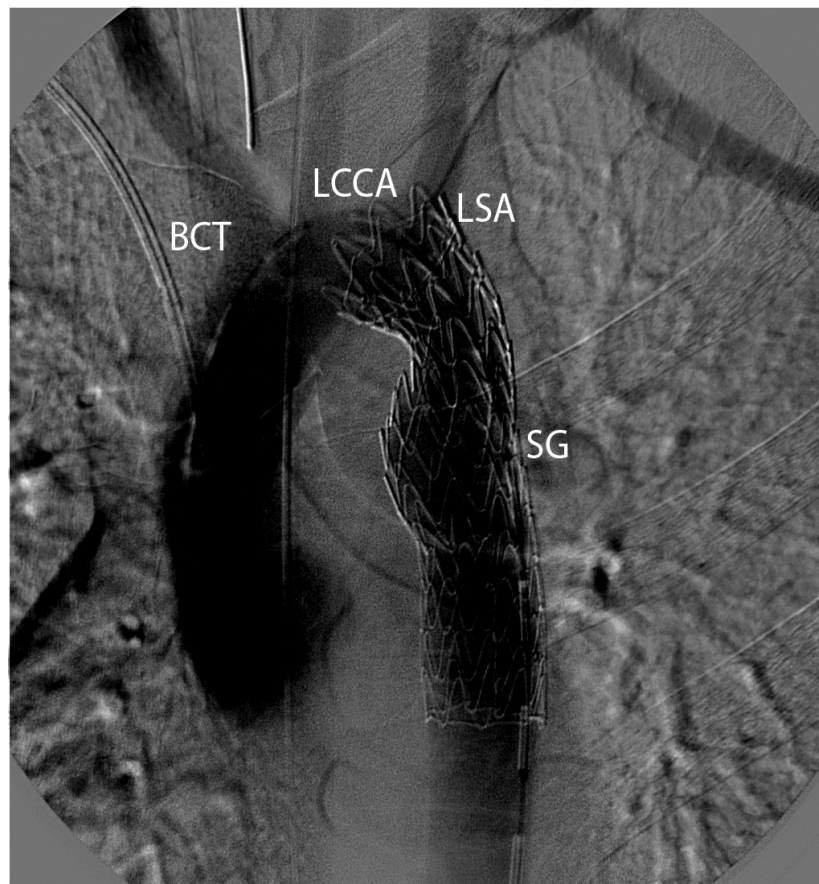


**Figure 1.** Arteriography of traumatic thoracic aorta rupture at the level of the isthmus: The traumatic thoracic aortic rupture illustrated in picture above was obtained through an arteriography and has the appearance of a pseudoaneurysm (BCT: Brachiocephalic Trunk, LCCA: Left Common Carotid Artery, LSA: Left Subclavian Artery, PA: Pseudoaneurysm).



**Figure 2. Stent Graft Placement:** This figure depicts an aortogram showing the Stent Graft (SG) placement near the left subclavian artery ostium (BCT: Brachiocephalic Trunk, LCCA: Left Common Carotid Artery, LSA: Left Subclavian Artery, PA: Pseudoaneurysm, SG: Stent Graft).





**Figure 3.** Deployment of the Stent Graft: Final aortogram showing the stent graft deployment with partial coverage of the left subclavian artery and exclusion of the descending aorta pseudoaneurysm (BCT: Brachiocephalic Trunk, LCCA: Left Common Carotid Artery, LSA: Left Subclavian Artery, SG: Stent Graft).

Advantages of this method are:

1. A minimally invasive procedure with a small wound made at the site of the femoral artery.
2. One lung ventilation is not necessary; however, mechanical ventilation is imperative during rehabilitation, which is of great significance for patients with broken ribs or pulmonary contusion.
3. Temporary aortic cross-clamping can be avoided; thus, reducing the risk of splanchnic ischemia, paraplegias and the need of an extracorporeal circulation.
4. Large heparin doses are not necessary due to the extracorporeal support system resulting in a decrease in the number of hemorrhagic complications, which is of great importance for patients with multiple aggressive injuries such as brain trauma or hip fractures.
5. It is a very efficient and fast procedure that needs fewer blood transfusions, and a shorter hospital admission for patients with no other comorbidities.

Nevertheless, complications due to the nature of the endovascular procedure remain. Distal thromboembolic events, stent migration, extended vessel dissection or type A endoleak in young individuals with angulation of the aortic arch are possible risk complications that may occur with the use of single linear grafts at the isthmus site. Additionally, in many cases, the ostium of the left subclavian artery needs to be covered adequately in order to acquire enough length for the proximal landing zone. However, in recent years it has been shown that ischaemia and claudication are infrequent, hence there is no need for postoperative revascularization of the limb. Furthermore, the relatively small diameter of the femoral artery (<8mm), the pre-existing stenosis, kinking of the iliac axis and small thoracic aorta in young patients, with large diameter transfer devices which bear the advancement and proper deployment of the graft to be difficult to perform. Finally, a close follow-up with consecutive CT scans is required for two main reasons. First, due to the younger age demographic of patients with ruptured isthmus, second this is a relatively recent developed technique with little evidence from retrospective

cohort studies, that have not yet evaluated the structural integrity of the grafts over time.

This case report proves that endovascular treatment of acute traumatic thoracic aortic transection at the level of the isthmus is an easy, less invasive technique, with many confirmed short-term benefits. Further research and randomized trials need to be conducted to examine the long-term results.

**Place of Work:** Unit of Vascular Surgery, Nicosia General Hospital 215 Nicosia-Limassol Old Road, Strovolos, 2029, Nicosia, Cyprus

#### Acknowledgements

The authors would like to acknowledge Mrs. Karen Plummer for the critical revision of the article.

#### References

- Cullen, E. L., Lantz, E. J., Johnson, C. M. & Young, P. M. (2014). Traumatic aortic injury: CT findings, mimics, and therapeutic options. *Cardiovasc Diagn Ther*, 4, 238-44.
- Di Marco, L., Pacini, D. & Di Bartolomeo, R. (2013). Acute Traumatic Thoracic Aortic Injury: Considerations and Reflections on the Endovascular Aneurysm Repair. *Aorta (Stamford)*, 1, 117-22.
- Fabian, T. C., Richardson, J. D., Croce, M. A., Smith, J. S., Jr., Rodman, G., Jr., Kearney, P. A., Flynn, W., Ney, A. L., Cone, J. B., Luchette, F. A., Wisner, D. H., Scholten, D. J., Beaver, B. L., Conn, A. K., Coscia, R., Hoyt, D. B., Morris, J. A., Jr., Harviel, J. D., Peitzman, A. B., Bynoe, R. P., Diamond, D. L., Wall, M., Gates, J. D., Asensio, J. A., Enderson, B. L. & et al. (1997). Prospective study of blunt aortic injury: Multicenter Trial of the American Association for the Surgery of Trauma. *J Trauma*, 42, 374-80; discussion 380-3.
- Pauls, S., Orend, K. H., Sunder-Plassmann, L., Kick, J. & Schelzig, H. (2007). Endovascular repair of symptomatic penetrating atherosclerotic ulcer of the thoracic aorta. *Eur J Vasc Endovasc Surg*, 34, 66-73.
- Reed, A. B., Thompson, J. K., Crafton, C. J., Delvecchio, C. & Giglia, J. S. (2006). Timing of endovascular repair of blunt traumatic thoracic aortic transections. *J Vasc Surg*, 43, 684-8.
- Rousseau, H., Dambrin, C., Marcheix, B., Richeux, L., Mazerolles, M., Cron, C., Watkinson, A., Mugniot, A., Soula, P., Chabbert, V., Canevet, G., Roux, D., Massabuau, P., Meites, G., Tran Van, T. & Otal, P. (2005). Acute traumatic aortic rupture: a comparison of surgical and stent-graft repair. *J Thorac Cardiovasc Surg*, 129, 1050-5.

Walsh, S. R., Tang, T. Y., Sadat, U., Naik, J., Gaunt, M. E., Boyle, J. R., Hayes, P. D. & Varty, K. (2008). Endovascular stenting versus open surgery for thoracic aortic disease: systematic review and meta-

analysis of perioperative results. *J Vasc Surg*, 47, 1094-1098.  
Williams, J. S., Graff, J. A., Uku, J. M. & Steinig, J. P. (1994). Aortic injury in vehicular trauma. *Ann Thorac Surg*, 57, 726-30.